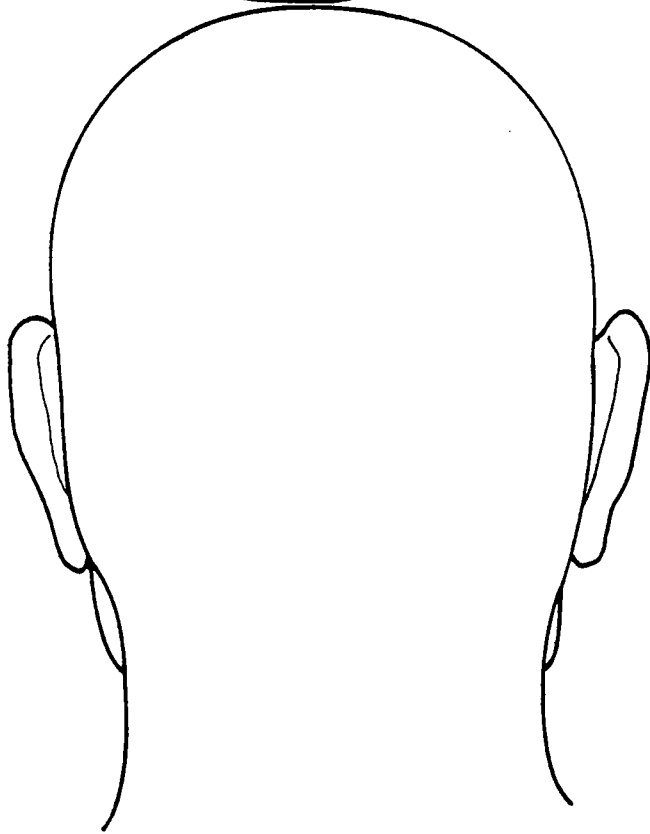
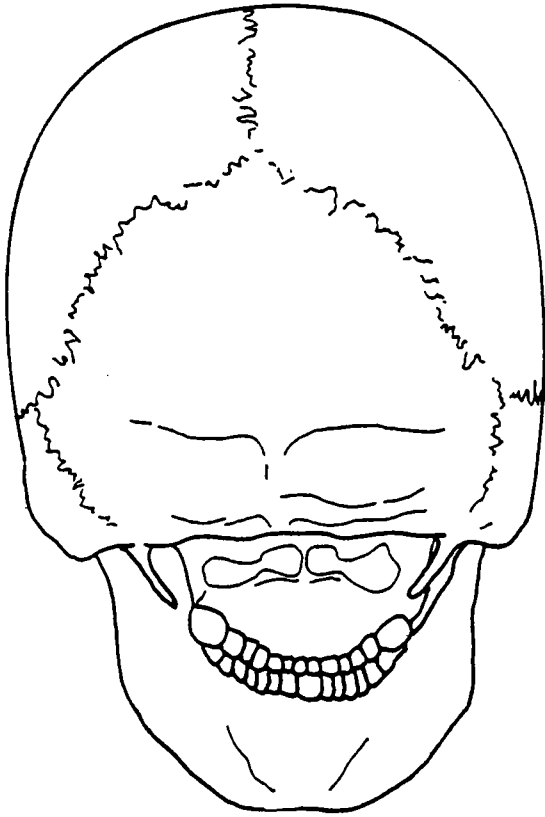
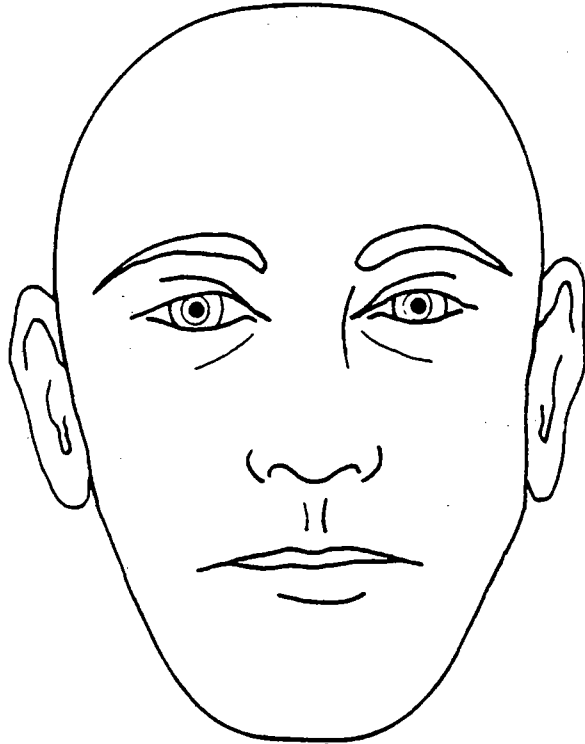
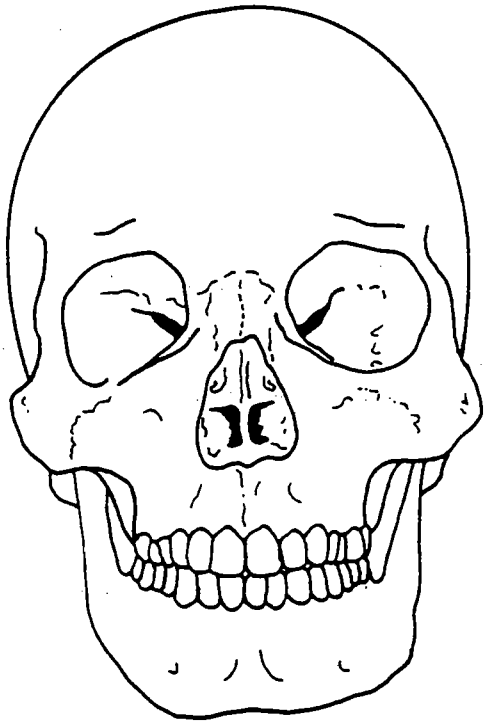


HEAD - SURFACE AND SKELETAL ANATOMY, ANTERIOR AND POSTERIOR VIEWS

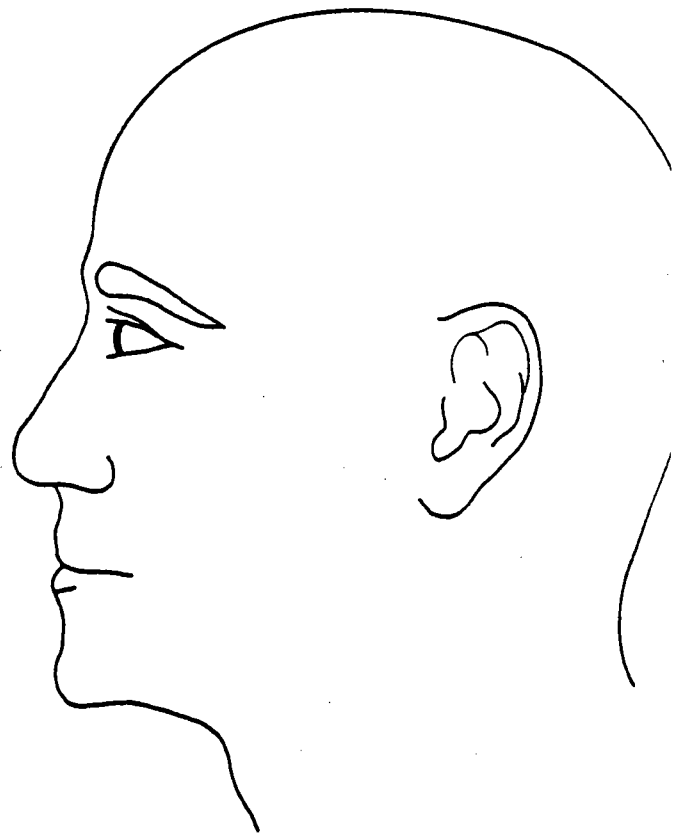
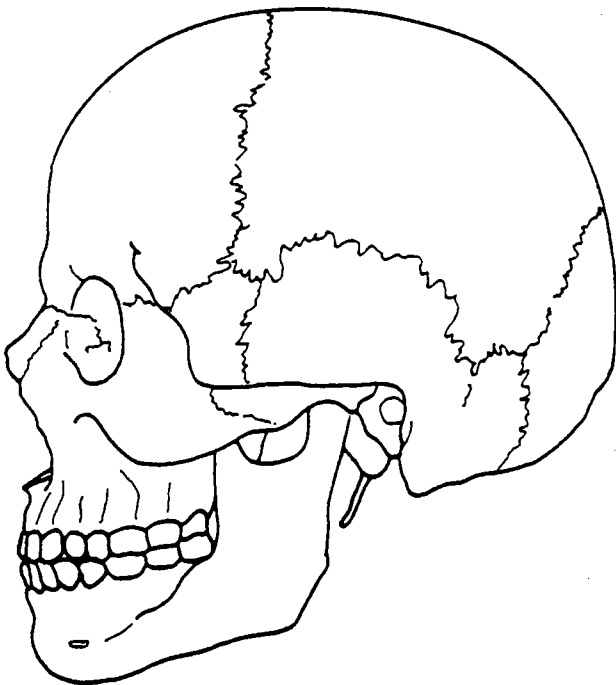
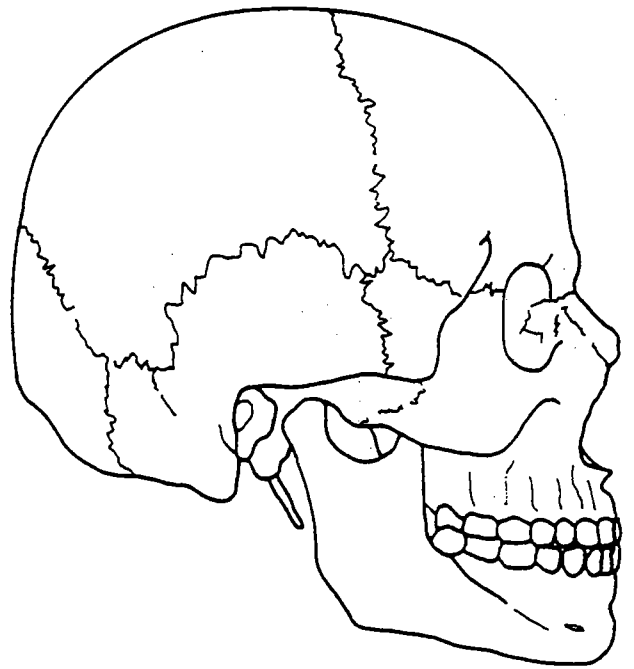
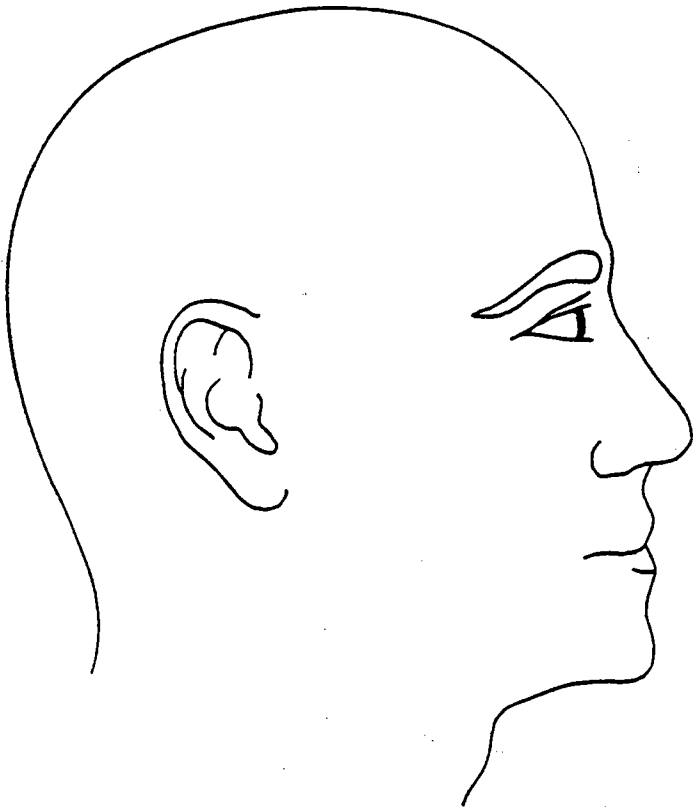


Name _____

Case No. _____

Date _____

HEAD - SURFACE AND SKELETAL ANATOMY, LATERAL VIEW

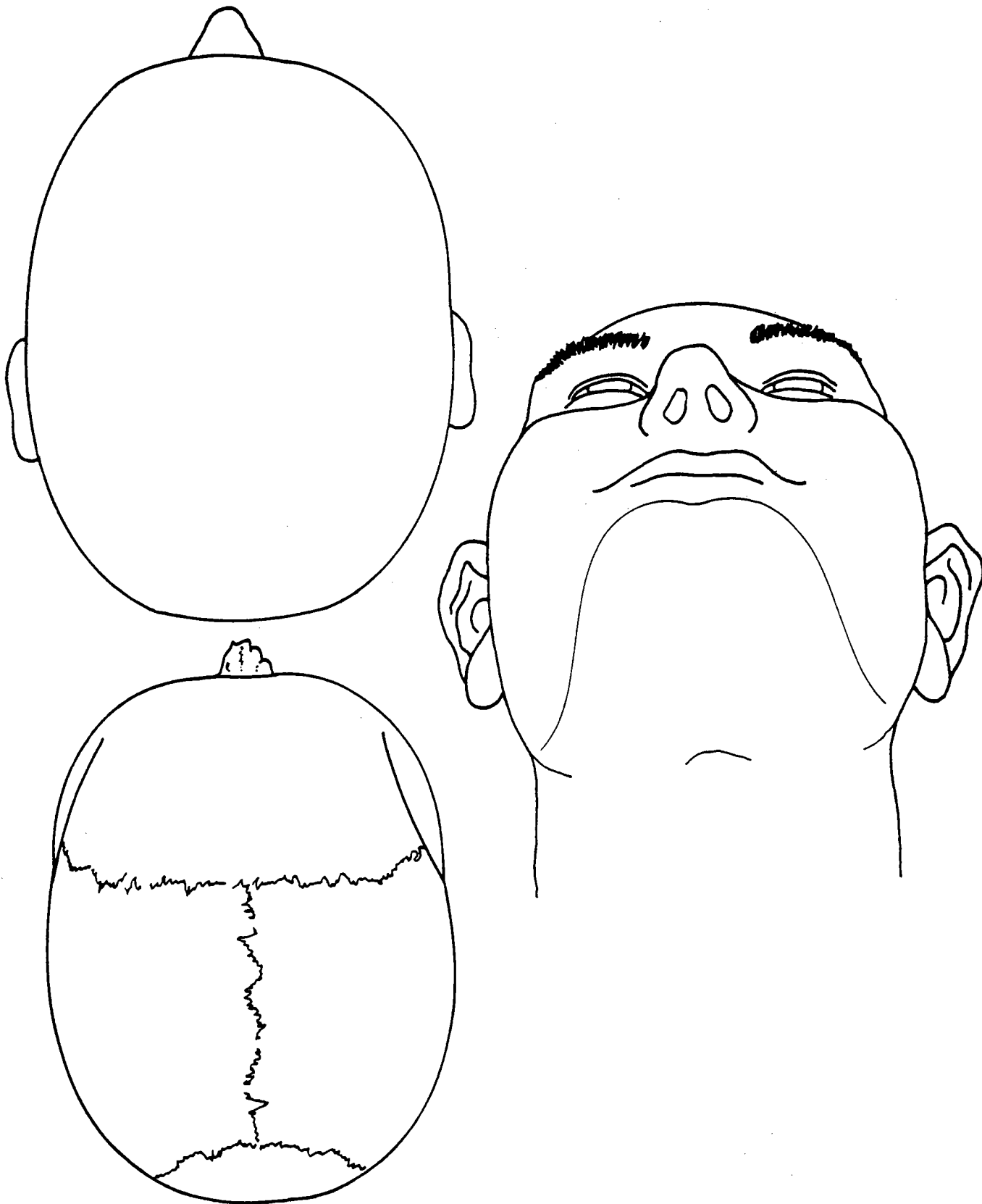


Name _____

Case No. _____

Date _____

HEAD - SURFACE AND SKELETAL ANATOMY, SUPERIOR VIEW - INFERIOR VIEW OF NECK

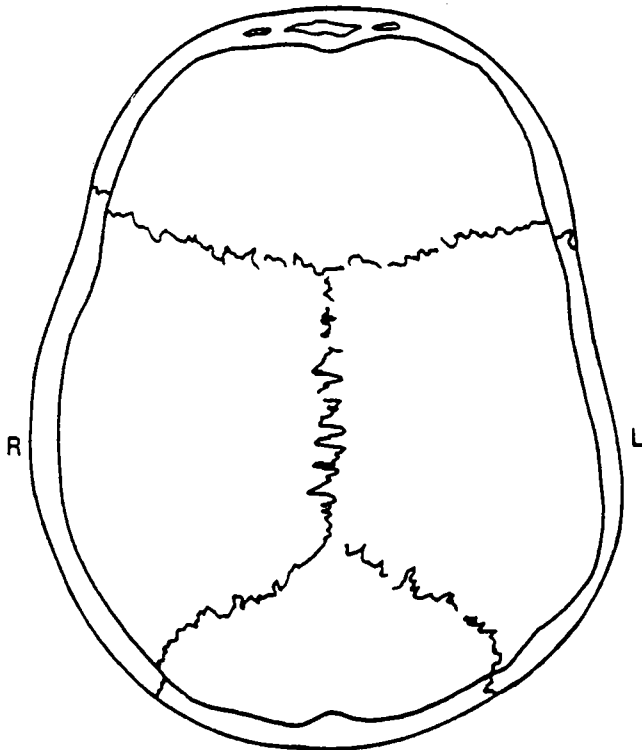
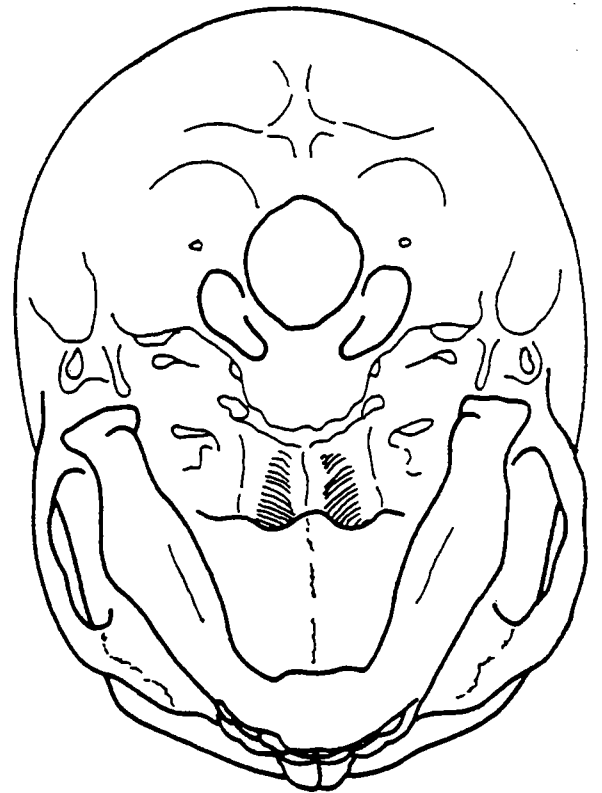
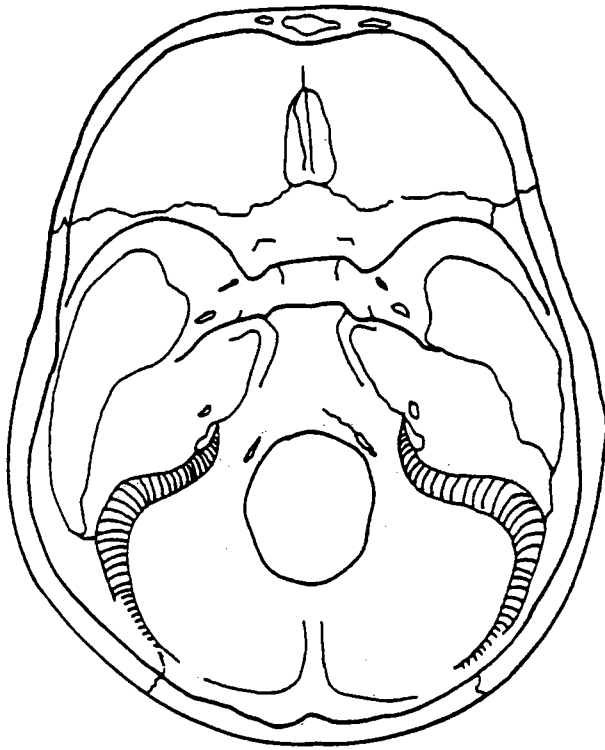


Name _____

Case No. _____

Date _____

SKULL - BASE, INFERIOR AND SUPERIOR VIEWS (PLUS CALVARIUM)



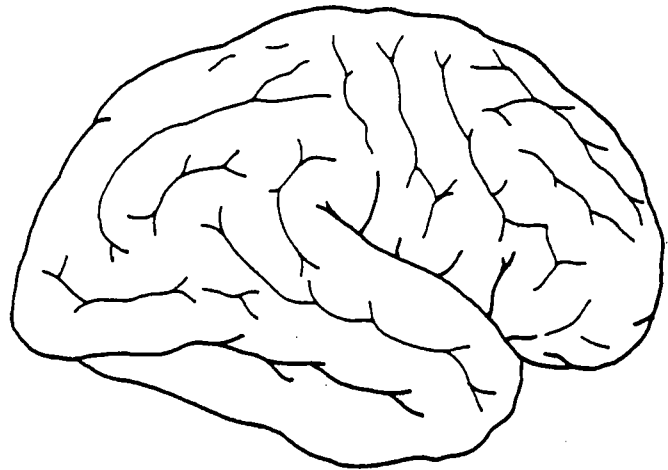
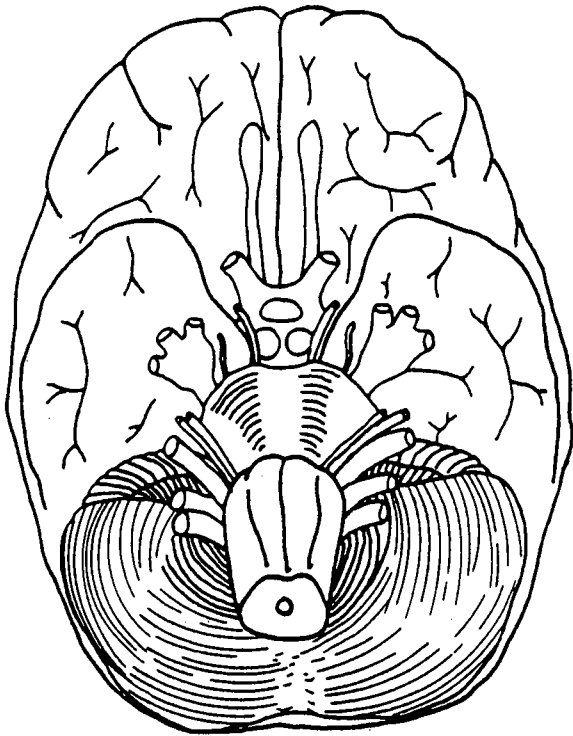
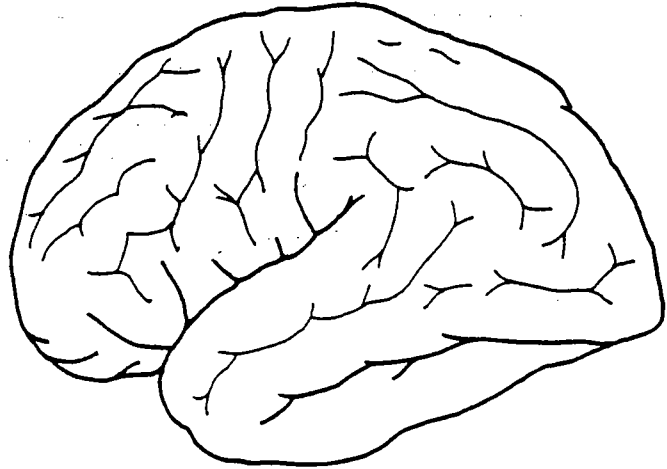
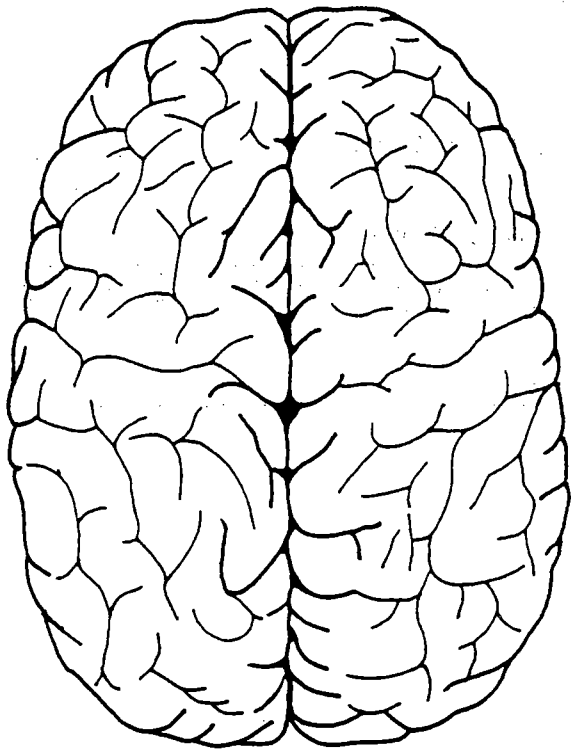
INNER VIEW OF SKULL

Name _____

Case No. _____

Date _____

BRAIN - SUPERIOR, INFERIOR, AND LATERAL VIEWS



Name _____ Case No. _____

Date _____

STAB WOUND CHART

NAME _____ City or County _____

		WOUND NO.									
		1	2	3	4	5	6	7	8	9	10
1. Location of wound:	Head										
	Neck										
	Chest										
	Abdomen										
	Back										
	Arm < Right										
	Left										
	Leg < Right										
	Left										
	2. The skin wound is:	Horiz.									
Vert.											
Oblique											
3. Centimetres from wound to:	Top of head										
	Right of midline										
	Left of midline										
4. Wound size in millimetres	Width										
	Length										
	Diam.										
5. Direction of wound:	Backward										
	Forward										
	Upward										
	Downward										
	Medially										
	Laterally										

Photographs made: Yes _____ No _____

REMARKS:

Examined by: _____

Date: _____

FIREARM WOUND CHART

NAME _____ CASE NO. _____

		WOUND NO.											
		1		2		3		4		5		6	
		Ent.	Ex.	Ent.	Ex.	Ent.	Ex.	Ent.	Ex.	Ent.	Ex.	Ent.	Ex.
1. Location of wound:	Head												
	Neck												
	Chest												
	Abdomen												
	Back												
	Right Arm <												
	Left												
	Right Leg <												
	Left												
2. Size of wound: (Centimetres)	Diam.												
	Width												
	Length												
3. Centimetres from wound to:	Top of head												
	Right of midline												
	Left of midline												
4. Firearm Residue:	On skin												
	Clothing												
	Absent												
5. Direction of missile through body:	Backward												
	Forward												
	Downward												
	Upward												
	To right												
	To left												
6. Missile Recovered:	Probable Calibre												
	Shotgun												

Photographs: _____ X-rays: _____

REMARKS: